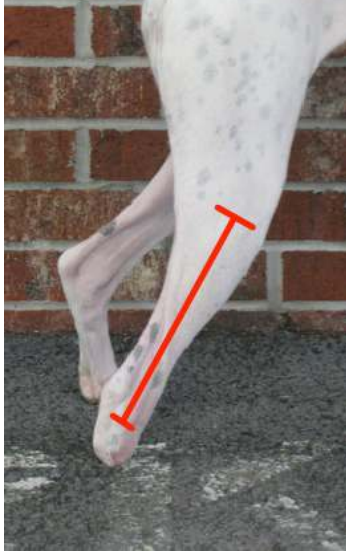



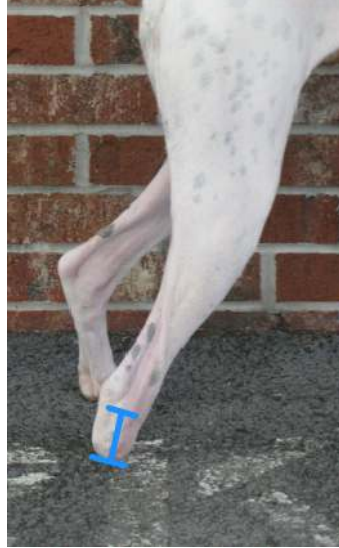Patient \_\_\_\_\_ Client \_\_\_\_\_

Breed \_\_\_\_\_ Age \_\_\_\_\_ Lbs \_\_\_\_\_

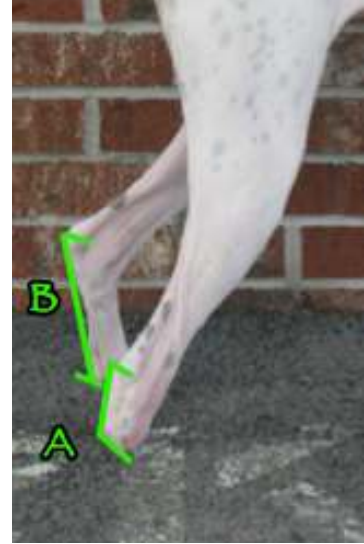
**Below Tarsus Prosthetic Measurement Form**



**1. Fibular Head - Lateral Malleolus: \_\_\_\_\_**



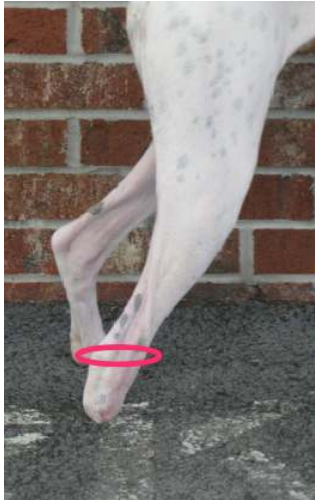**2. Lateral Malleolus - End of Limb \_\_\_\_\_**



**3. (A) Calcaneus - end of limb \_\_\_\_\_**

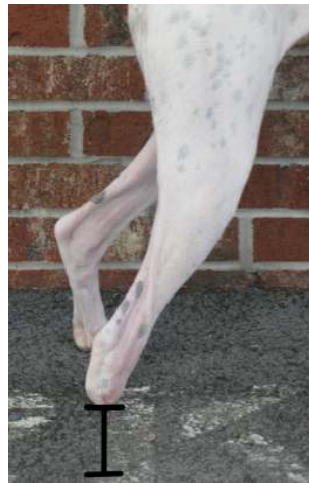-follow angle of metatarsals-

**(B) "GOOD LIMB" Calcaneus - Ground \_\_\_\_\_**

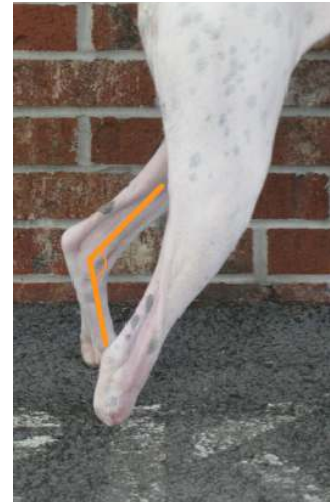

**4. Tarsus Circumference \_\_\_\_\_**

-include Calcaneus & Malleoli-



**5. End of limb - ground (3B-3A; seem right?) \_\_\_\_\_**



**6. Standing angle of tarsus of "GOOD LIMB" (fibular head, lateral malleolus, 5<sup>th</sup> met head) \_\_\_\_\_**

**7. What is the ROM of the affected tarsus? \_\_\_\_\_**

**8. Any limitations? \_\_\_\_\_**

**9. Please email or send pictures and if possible x-rays of the affected limb.**